

Papillary Carcinoma in Median Aberrant Thyroid (Ectopic) - Case Report

ASHWIN HEBBAR. K¹, SHASHIDHAR. K², VIJAYA LAXMI DESHMANE³, VEERENDRA KUMAR⁴, RAVI ARJUNAN⁵

ABSTRACT

Median ectopic thyroid may be encountered anywhere from the foramen caecum to the diaphragm. Non lingual median aberrant thyroid (incomplete descent) usually found in the infrahyoid region and malignant transformation in this ectopic thyroid tissue is very rare. We report an extremely rare case of papillary carcinoma in non lingual median aberrant thyroid in a 25-year-old female. The differentiation between a carcinoma arising in the median ectopic thyroid tissue and a metastatic papillary carcinoma from an occult primary in the main thyroid gland is also discussed.

Keywords: Thyroid malignancy, Total thyroidectomy

CASE REPORT

A 25-year-old female was presented with gradually increasing swelling in the neck since six months in May 2013. On examination, swelling of size about 4x4 cms was found just below the hyoid bone and it was not moving with deglutition and protrusion of the tongue. Ultrasound neck revealed ectopic thyroid gland in sub-hyoid position with absence of thyroid in its normal pretracheal position (median aberrant thyroid). I131 radioiodine scan showed an arrest in the descent of the thyroid gland to its normal anatomical position. No other neck nodes were identified [Table/Fig-1]. Fine needle aspiration cytology of the swelling revealed only adenomatous hyperplasia of the gland. Patient was hypothyroid on thyroid function test and was put on L-thyroxine for 15 days before surgery. With all these investigation excision of median aberrant thyroid was planned. Surgery and postoperative recovery was uneventful. Histopathology was surprisingly reported as follicular variant of papillary carcinoma with intact capsule. Since iodine scintiscan showed no evidence of metastasis regular follow-up was advised.

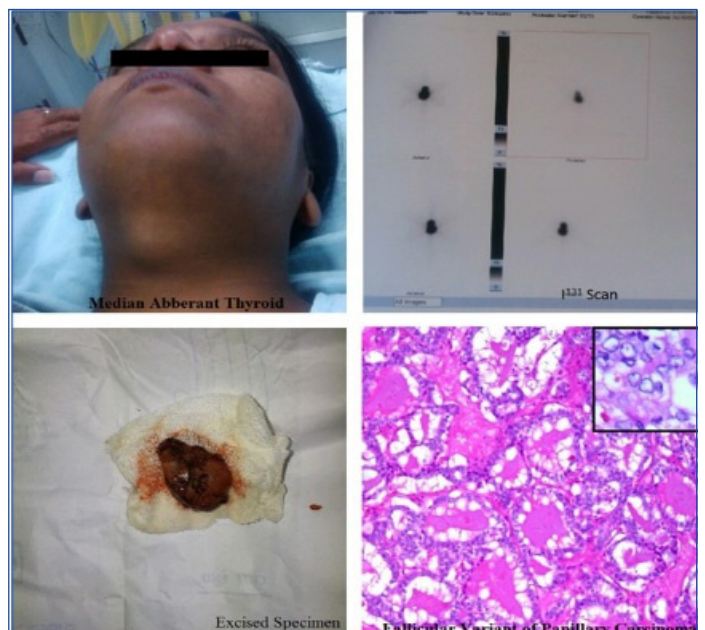
DISCUSSION

Median aberrant thyroid gland is defined as incomplete descent of the thyroid gland from the foramen caecum to its original position in pretracheal region in the lower neck [1]. lingual thyroid is the most common position of the median aberrant thyroid. Non lingual median aberrant thyroid usually found in the infrahyoid region and is usually very rare [2].

Most of the carcinomas in the ectopic thyroid gland reported in the literature were from the thyroglossal duct cyst remnant with normal thyroid gland in position (median ectopic thyroid) and lingual thyroid (median aberrant thyroid). We are reporting a rare case of non-lingual median aberrant thyroid carcinoma and reviewing the literature of carcinoma arising from other median ectopic thyroid and discussing the differentiation between this and metastatic papillary carcinoma arising from occult primary in main thyroid gland.

Embryologically, the central portion of the thyroid gland descends from its origin at the foramen caecum of the tongue to its normal adult location below the hyoid bone and anterior to the trachea and laryngeal cartilages. During this migration, the gland remains connected to the floor of the fetal pharyngeal gut by means of the thyroglossal duct [3]. If this duct subsequently fails to atrophy, it may give rise to thyroglossal duct cyst presenting as a mass in the anterior midline of the neck [4,5]. Because of this embryologic

development, thyroid tissue may be situated anywhere along the course of the thyroglossal duct from the base of the tongue to the anterior neck. Thus, thyroglossal duct remnants and the accompanying ectopic thyroid rests may be located in lingual, sublingual, suprahyoid or infrahyoid positions [3], 5 to 45% of the thyroglossal duct cyst contain in their walls apparently normal ectopic thyroid tissue. The percentage undoubtedly varies depending on how thoroughly the tissue surrounding the cyst is examined. Ectopic thyroid tissue is probably associated with thyroglossal ducts or cysts more commonly than has been reported previously in the literature [2]. Thyroid tissue associated with a thyroglossal duct cyst should be differentiated from "lingual thyroid". Some authors restrict the latter term to those cases in which the thyroid never descended in fetal life. The only thyroid tissue in these patients is located at the base of the tongue under the region of foramen caecum (lingual median aberrant thyroid) [6]. This forms the most common type of median aberrant thyroid where normal thyroid is absent in its pretracheal position in the lower neck. The other rare variety of non lingual median aberrant thyroid is usually found in the subhyoid position (thyrohyoid).



[Table/Fig-1]: Papillary carcinoma in median aberrant thyroid

Any of the lesions which affect the main thyroid gland may also involve these ectopic thyroid remnants, including cysts, nodular goiter and carcinoma [7] Primary thyroid carcinomas arising from ectopic thyroid tissue are uncommon and have been reported to arise from thyroid tissue in the thyroglossal ducts, lateral aberrant thyroid tissue, lingual thyroid, mediastinal and struma ovarii. Most of the tumours in the ectopic locations have been papillary, mixed papillary and follicular carcinomas or Hurthle cell tumours [8].

Most of the literatures explain the occurrence of primary papillary carcinoma in the ectopic thyroid tissue remnant in thyroglossal duct and lingual median aberrant thyroid. About 100 cases of primary papillary carcinoma in ectopic thyroid gland have been so far described in the literature [9,10]. Here, we reported a rare case of papillary carcinoma in the non-lingual median aberrant thyroid, where normal thyroid was absent in its pretracheal position in the lower neck.

Some authors consider that any thyroid tissue in cervical lymph nodes represents metastatic disease. However, most recent investigators agree that apparently non neoplastic thyroid tissue, consisting of small nests of normal appearing colloid filled follicles, without papillary areas, can be found ectopically in the cervical lymph nodes (usually in the capsule). Thyroid tissue with papillary areas noted with in the substance of cervical lymph nodes probably always represents a metastasis (lateral aberrant thyroid) [11].

Virginia A. et al. reported in the literature 76 collected cases of carcinoma originating in the thyroglossal duct cysts or other non lingual medially displaced thyroid tissue [2]. Histologically, 87% were papillary carcinomas. Others were adenocarcinoma, squamous cell carcinoma, follicular carcinoma and mixed follicular and papillary carcinomas.

Finding of papillary carcinoma separate from the thyroid gland raises the possibility of an occult primary in the thyroid. Some authors believe that such a finding anywhere in the neck indicates that carcinoma must be present in the thyroid gland itself [12]. If the tissue submitted to the pathologist as a thyroglossal specimen demonstrates only papillary carcinoma on routine sections, then the pathologist should submit the entire specimen for histological examination to search for the presence of non neoplastic thyroglossal duct remnants and/or ectopic normal thyroid follicles. Should such tissue be found, then the lesion less likely represents a metastasis and is more apt to be a primary carcinoma arising in ectopic thyroid. Therefore, it may be suggested that total thyroidectomy might not necessarily be indicated as a routine procedure following the finding of a papillary carcinoma in the thyrohyoid region, especially if the normal thyroid tissue or thyroid duct remnants are found. However, since the possibility exists that a carcinoma may also be present in the thyroid gland itself, the thyroid should be carefully palpated and also studied by scan [13]. Should the lesion be discovered, the thyroid should be explored in the usual manner. If no abnormality is detected clinically, the patient should be followed at regular intervals to determine if a lesion becomes detectable in the thyroid gland itself at some later date [2]. We consider the management outlined above to be an acceptable alternative to total thyroidectomy in these cases. A similar problem in the management arises when a papillary carcinoma has been found in one lobe of the thyroid. In this situation many surgeons recommended total thyroidectomy, since from 18-75% of the contra lateral lobes contain tumour when examined pathologically [14,15]. In our institution total thyroidectomy and paraglandular lymph node dissection are usually performed for papillary carcinoma of the thyroid.

Jay Fish et al., revived 21 cases of lingual thyroid carcinoma from various literature [1]. Fourteen patients were female and seven patients were male. A thyroid gland was also present in two of the seven patients. In 13 cases only local excision was performed. In

two other cases it was combined with bilateral neck dissection. Other cases were treated with radioiodine. Local recurrence after surgery was reported in three cases and death from cancer in one case.

Gross reported three cases of infrahyoid masses which were diagnosed as thyroglossal duct cysts but found at surgery to be solid masses of ectopic thyroid tissue [16]. He recommends incising the mass when there is question as to its nature. If it proves to be benign midline thyroid tissue and further exploration reveals absence of a normal pretracheal gland, the mass can be sectioned in a mid sagittal plane and the two halves tucked beneath the strap muscle without disturbing their blood supply. Two of the three cases treated in this manner with excellent functional and cosmetic results.

In contrast to lingual thyroid carcinomas, the discovery of carcinoma in a thyroglossal duct remnant and median aberrant thyroid generally comes as a surprise and frequently not until the pathologist examine the permanent paraffin sections. If there is no evidence of lymph node involvement, wide local excision of the mass should suffice. This should include excision of the vestigial tract in the hyoid and lingual areas.

CONCLUSION

Median aberrant thyroid gland forms a part of median ectopic thyroid gland where a normal thyroid gland is absent in its pretracheal position. Lingual thyroid forms the most common variety of this. But papillary carcinoma arising from non-lingual median aberrant gland is very rare and only few cases have been reported in the literature. The differentiation between carcinoma arising in median ectopic thyroid tissue and a metastatic papillary carcinoma from an occult primary in the main gland is also important. If latter is ruled out as we discussed earlier, wide local excision of the mass should suffice. Therefore we believe that total thyroidectomy might not necessarily be indicated as a routine procedure following the finding of a papillary carcinoma in the thyrohyoid region (median ectopic thyroid), especially if the normal thyroid tissue or thyroid duct remnants are found.

REFERENCES

- [1] Jay Fish, Robert M Moore. Ectopic Thyroid Tissue and Ectopic Thyroid Carcinoma- A Review of Literature and Report of a Case. *Annals of Surgery*. 1963;152(2): 212-22.
- [2] Virginia A, et al. Carcinoma arising in median ectopic thyroid (including thyroglossal duct tissue). *Cancer*. 1974; 34:1303-15.
- [3] Rogers WM. Anomalous embryological development of the thyroid. In *The Thyroid*, SC. Werner and SH. Ingbar, Eds. New York, Harper and Row. 1971: 312-7.
- [4] Pollock and Stevenson. Cysts and sinuses of thyroglossal duct. *American Journal of Surgery*. 1966;112: 225-32.
- [5] Strickland, et al. Ectopic thyroid gland simulating thyroglossal duct cysts. *JAMA*. 1969; 208:307-10.
- [6] Montgomery ML. Lingual thyroid- Comprehensive review. *Western Journal of Surgery*. 1936; 44:442-6.
- [7] Smithers DW. Carcinoma associated with thyroglossal duct anomalies. In *Tumours of the Thyroid Gland*. Eds London, E. and S. Livingstone. 1970: 155-61.
- [8] Bhavin C, et al. Ectopic Thyroid Cancer. *Annals of Thoracic Cardiovascular Surgery*. 2007;13(2):122-4.
- [9] Angelena Fumarola, et al. Thyroid carcinoma arising in ectopic thyroid tissue within a neck brachial cyst. *World Journal of Surgical Oncology*. 2006; 4:24.
- [10] Cevera PFJ, et al. Ectopic primitive papillary carcinoma: report of a fatal case and review of literature. *Acta Otorhinolaryngol Esp*. 1994; 45:124-7
- [11] Sampson RJ, et al. Metastasis from occult primary carcinoma. *Cancer*. 1970; 25:803-11.
- [12] Nuttall FQ. Cystic metastasis from papillary adenocarcinoma of the thyroid with comments concerning carcinoma associated with thyroglossal remnants. *American Journal of Surgery*. 1965; 109:500-5.
- [13] George Nossios, Panagiotis Anagnostis, Dimitrios G Goulis, Dimitrios Lappas and Konstantinos Natsis. Ectopic thyroid tissue: anatomical, clinical and surgical implications of a rare entity. *European Journal of Endocrinology*. 2011;165:375-82
- [14] Black BM, et al. Multicentricity of papillary carcinoma of thyroid. *Journal of Clinical Endocrinology and Metabolism*. 1960; 20:130-5.
- [15] Klubo-Gwiedzinska J, et al. Ectopic cervical thyroid carcinoma-review of literature with illustrative case series. *Journal of Clinical Endocrinol Metabolism*. 2011;96(9):2684-91.
- [16] Gross RE. *Surgery of infancy and childhood*. Philadelphia, WB. Saunders Co. 1953; 945.

PARTICULARS OF CONTRIBUTORS:

1. Assistant Professor, Department of General Surgery, Shimoga Institute of Medical Sciences, Shimoga, Karnataka, India.
2. Associate Professor, Department of ENT, Karnataka Institute of Medical Sciences, Hubli, Karnataka, India.
3. Professor and Head, Department of Surgical Oncology, Kidwai Memorial Institute of Oncology, Bangalore, Karnataka, India.
4. Professor, Department of Surgical Oncology, Kidwai Memorial Institute of Oncology, Bangalore, Karnataka, India.
5. Associate Professor, Department of Surgical Oncology, Kidwai Memorial Institute of Oncology, Bangalore, Karnataka, India.

NAME, ADDRESS, E-MAIL ID OF THE CORRESPONDING AUTHOR:

Dr. Ashwin Hebbar. K,

39. "Krutika", 3rd Main, 2nd Cross, Gururagavendra Nagar, J.P.Nagar 7th Phase, Bangalore-560078 Karnataka, India.

Phone: +919986042864, E-mail: hebbar2000@yahoo.com

Date of Submission: **Sep 11, 2013**

Date of Peer Review: **Jan 01, 2014**

Date of Acceptance: **May 01, 2014**

Date of Publishing: **Jun 20, 2014**

FINANCIAL OR OTHER COMPETING INTERESTS: None.